

# Treatment Effect of Levodopa in Amblyopia Evaluated by Functional MRI

J. C. Huang<sup>1</sup>, C. I. Yang<sup>2</sup>, M. L. Yang<sup>2</sup>, Y. L. Wan<sup>3</sup>, J. F. Tsai<sup>2</sup>, Y. Y. Wai<sup>1</sup>, H. L. Liu<sup>1</sup>

<sup>1</sup>MRI Center, Chang Gung Memorial Hospital and School of Medical Technology, Chang Gung University, Kweishan, Taoyuan, Taiwan, <sup>2</sup>Dept. of Ophthalmology, Chang Gung Memorial Hospital, Kweishan, Taoyuan, Taiwan, <sup>3</sup>Dept. of Diagnostic Radiology, Chang Gung Memorial Hospital, Kweishan, Taoyuan, Taiwan

## Synopsis

Functional MRI (fMRI) was applied to amblyopes with monocular amblyopia before and after levodopa treatment. fMRI images were acquired in two runs with visual stimulation delivered through the sound and the amblyopic eyes, respectively. The experiment was performed before and after subject's oral administration of levodopa/carbidopa (0.5/0.12mg/kg). Our study demonstrated that the volume ratio between the amblyopic and sound eye stimulation significantly increased after the treatment. This finding supports the previous studies of levodopa effect on amblyopia at the visual cortical level, and suggests that fMRI can be a useful tool in assessing changes of visual cortical activity after levodopa.

## Introduction

Amblyopia is a unilateral or bilateral reduction of best-corrected visual acuity that cannot be attributed directly to the effect of any structural abnormality of the eye or the posterior visual pathway. It is caused by abnormal visual experience early in life, usually resulting from ocular misalignment or uncorrected refractive error. Gottlob et al. found that, a single dose of levodopa, a precursor of the dopamine, with a combination of a peripheral decarboxylase inhibitor (e.g. benzerazide or carbidopa) can temporarily improve contrast sensitivity in the amblyopic eyes in adults (1). The dopamine is presented in retinal amacrine and interplexiform cells in humans as a neurotransmitter, and is likely involved in the visual information transmission to the visual cortex (2). Leguire et al. reported that contrast sensitivity function was improved in patients after a single dose and a 7-week regimen of levodopa, combined with part-time occlusion (3, 4). Recently, fMRI has been utilized to measure the neuronal activity within visual cortical areas in patients with amblyopia (5, 6). In the present study, the purpose is to apply fMRI techniques in the investigation of the changes of visual cortical activity in patients with amblyopia after the levodopa treatment.

## Method

Four amblyopes aged from 13 to 17 years old were enrolled in this study. The indications, risks and benefits of the procedures were well explained to the patients or their family. The best-corrected visual acuities (BCVAs) of their sound eye were all 1.0, while that of their amblyopic eye were 0.3, 0.3, 0.04 and 0.3, respectively. All patients received levodopa and part-time (3 hours/day) occlusion of the sound eye. Levodopa/carbidopa, in the dosage of 0.5/0.12 mg/kg was administered orally three times per day for 7 weeks. fMRI experiments were performed on a 1.5-T Magnetom Vision MRI scanner. Two separate fMRI scans were performed on sound eye and amblyopic eye, respectively. Each scan contains four resting-state blocks, interleaved by three stimulation-state blocks. Each block lasts for 30 seconds. A full field circular checkerboard flashing at 8 Hz was presented on a goggle display system as the visual stimuli. The visions of each subject were corrected to the BCVAs using lenses during the experiments. The subject's head was restrained in a molded plastic facial mask to reduce motion. A single-shot T<sub>2</sub>\*-weighted gradient-echo echo-planar imaging (EPI) sequence was used for fMRI imaging. 17 slices along the direction of the calcarine fissure was imaged to cover the visual areas and most other parts of the brain. The imaging parameters were as follows: slice thickness=5mm, in-plane spatial resolution=3.3×3.3mm<sup>2</sup>, number of measurement=105, and TR/TE/FA=2000ms/60ms/90°. For anatomical detail, a high-resolution (1x1mm<sup>2</sup>) T<sub>1</sub>-weighted image was acquired with the same slice thickness and location being identical to that used in the functional imaging. For data processing (7), activation maps were calculated by comparing images acquired during the stimulation states and those during the resting states, using an unpaired students' *t*-test with a threshold of 2.4 (p<0.01). For each subject, the volume of significantly activated voxels within the visual cortex were used to compare the neuronal activity induced by visual stimulation through the sound eye and the amblyopic eye, before and after the treatment. The ratio of the activation volumes from the amblyopic and sound eye stimulation was calculated to further investigate the treatment effect.

## Results

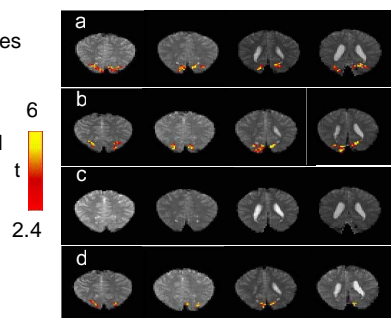
Fig. 1 shows the functional maps of visual cortical areas from one of the patients, before and after levodopa medication. With the sound eye stimulation (Fig. 1a, b), approximately identical locations and volumes of the activated voxels were observed before and after the treatment. For the amblyopic eye stimulation, no significant activation was detected before the treatment (Fig. 1c). However, after the treatment, significant activation was observed in the visual areas (Fig. 1d). Table 1 summarizes the volumes of the activated voxels in the visual cortical areas detected in all the four patients. With the sound eye stimulation, no significant difference was found in the fMRI volume measurement before and after levodopa medication (p=0.20). With the amblyopic eye stimulation, greater volume of activation was found after than before the administration of levodopa. However, p=0.09 did not reach the statistical criteria. The volume ratio from the amblyopic and sound eye stimulation showed a statistically significant improvement (p<0.05) after levodopa medication. Post-treatment BCVAs of the patients' sound eyes were 1.0, and that of their amblyopic eyes were 0.4, 0.5, 0.04, and 0.5, respectively. Improvement of BCVAs was observed to be in good agreement with the fMRI results.

Patient No.	Before levodopa			After levodopa		
	Sound eye (mm <sup>3</sup> )	Amblyopic eye (mm <sup>3</sup> )	Ratio	Sound eye (mm <sup>3</sup> )	Amblyopic eye (mm <sup>3</sup> )	Ratio
1	5826	3811	0.65	3921	4411	1.12
2	5499	6098	1.11	6697	9148	1.37
3	16172	381	0.02	11871	0	0
4	7623	0	0	7841	4520	0.58
Mean	8780	2573	0.45*	7852	4520	0.77*
±SEM	±2507	±1454	±0.27	±1649	±1868	±0.30

Table 1. Summarizes the volumes of the activated voxels.

\* p<0.05

Fig. 1. Functional maps of visual cortical areas.



## Discussion

The results demonstrated that there was no effect on primary visual cortical activation by visual stimulation to the sound eye. For the amblyopic eye stimulation, there was some improvement on the spatial extents of fMRI signal after levodopa. However, it did not reach the statistical significance (p=0.09), which may be attributed to the limited number of patients, significant inter-subject variation that resulted from the poor visual activity of the subject 3 and/or different types of amblyopia (3), and the variance between the two experiments with relatively long interval, 7 weeks, performed before and after treatment. To minimize this possible effect, we calculated the volume ratio from the amblyopic and sound eye stimulation, and found a significant improvement (p<0.05) after levodopa. Our results showed that the treatment effects in improving visual function in amblyopes can now be observed in visual cortical activation using fMRI. To evaluate the sensitivity of fMRI as a tool for assessing the levodopa effect, studies with larger groups of patients are required and are currently under investigation in our research team.

## Reference

- Gottlob I., et al, Invest. Ophthalmol. Vis. Sci., 31, 776, 1990.
- Dyer R.S., et al, Exp. Neurol., 71, 326, 1981.
- Leguire L.E., et al, J. Pediatr. Ophthalmol. Strabismus., 29, 290, 1992.
- Leguire L.E., et al, J. Pediatr. Ophthalmol. Strabismus., 32, 143, 1995.
- Goodyear B.G., et al, J. Neurophysiol., 84, 1907, 2000.
- Choi M.Y., et al, Br. J. Ophthalmol., 85, 1052, 2001.
- Xiong J., et al, Hum. Brain Mapp., 3, 209, 1995