

Rapid Evaluation of Right Ventricular Volume and Mass Without Breath-holding Using Real-Time Interactive Cardiac Magnetic Resonance Imaging System

Shuichiro KAJI¹, Phillip YANG², Craig MEYER³, John M. PAULY⁴, Bob HU⁵

¹Kawasaki Medical School, 577, Matsushima, Kurashiki, Okayama Japan; ²Stanford University, Stanford University Hospital, Division of Cardiovascular Medicine, Stanford, CA ; ³Stanford University, Post Office Box 7642, Stanford, CA ; ⁴Stanford University, School of Engineering, 206 Packard Electrical Engineering, Stanford, California United States; ⁵Stanford University, School of Medicine, 300 Pasteur Drive, Stanford, California United States;

Introduction

The prognostic and therapeutic implications of both single and serial assessment of cardiac volumes, mass, and function are now well established in a variety of cardiac diseases. In particular, left ventricular volume and mass are powerful prognostic indicators in a variety of cardiac diseases. However, precise determination of the degree of right-sided volume overload is also very important in evaluating cardiac or pulmonary diseases as well as left ventricular volume measurements.

While magnetic resonance imaging (MRI) provides accurate assessment of cardiac volume and mass, previous techniques have been relatively slow and required ECG gating. In contrast, a newly developed cardiac MRI system allows continuous real-time dynamic acquisition and display of any scan plane at up to 30 images/s without ECG gating or breath-holding. We previously reported the usefulness of this real-time cardiac MRI in left ventricular volume measurements and validated cardiac measurements derived from the real-time MR imaging as compared with the well validated conventional cine MR imaging. However, right ventricular (RV) measurements derived from the real-time cardiac MRI were not validated yet. The purpose of this study was to validate RV measurements derived from the real-time cardiac MRI as compared with the well-validated conventional cine MRI.

Methods

Ten healthy subjects underwent the real-time cardiac MRI and cine MRI in the short axis orientation on a standard 1.5T MRI scanner. Conventional non-breath-hold cine MR images were acquired with 1.5T Signa MRI scanner (GE, Milwaukee, Wisconsin) employing 5 inch surface coil. Images were obtained by using a gradient-echo technique with flow and respiratory compensation. The following parameters were employed: an echo-time of 8.0 msec, a repetition time of 18 msec, a flip angle of 30 degrees, a slice thickness of 10 mm with no inter-slice gap, an acquisition matrix of 256x128, two excitations, and a 32cm field of view. After the scout images were obtained, both ventricles were imaged from the base to the apex in 9 to 12 double-angulated short-axis slices.

The real-time interactive MR imaging system requires a modest upgrade consisting of a workstation and a bus adapter to a conventional 1.5T Signa MRI scanner. This system accomplishes the following; 1) real-time image acquisition eliminating the need for cardiac or respiratory gating; 2) interactive selection of scan plane allowing immediate control of the desired view plane and 3) real-time image reconstruction and display providing instant image-based feedback. The following parameters were employed in this study: an echo-time of 4.6 msec, a repetition time of 30 msec, a flip angle of 30 degrees, a slice thickness of 7 mm with 0.2 mm inter-slice gap, and a 24 cm field of view with 2.7 mm inplane resolution.

Right ventricular end-systolic (RVESV) and right ventricular end-diastolic (RVEDV) volumes were obtained by integrating the areas and multiplying by the slice interval (slice thickness + slice gap). Stroke volume was the difference between RVEDV and RVESV. Right ventricular ejection fraction (RVEF) was calculated as stroke volume divided by RVEDV and expressed in percent. RV mass was calculated by multiplying the myocardial volume measured in the end-diastolic phase with the specific myocardial gravity (1.05 g/cm³).

Results

The actual acquisition time for real-time MR images was significantly shorter than that for cine MRI (2.0±0.3 versus 12.9±1.9 minutes, p<0.001). In addition, the total study time including localization was significantly shorter than that for cine MRI (9.0±2.1 versus 24.4±2.5 minutes, p<0.001). Both techniques yielded good quality images allowing RV volumetrics.

There was good agreement between real-time volumes and cine volumes. The RV measurements obtained with real-time cardiac MRI

showed close correlation with those obtained with conventional cine MRI (RVEDV: r=0.94, p<0.001, RVESV: r=0.95, p<0.001, RVEF: r=0.64, p<0.05, RV mass: r=0.90, p<0.005).

Discussion

Evaluation of RV function is feasible without breath-holding with the use of the real-time interactive MR imaging. Compared with the conventional cine MR imaging, real-time MR imaging shows markedly reduced acquisition time in the assessment of RV volumes and mass. We conclude that real-time MR imaging system is a valuable technique that provides accurate assessment of RV volumes and mass in a time-efficient manner.

References

1. Kerr AB, Pauly JM, Hu BS, et al. Real-time interactive MRI on a conventional scanner. *Magn Reson Med.* 1997;38:355-367.
2. Yang PC, Kerr AB, Liu AC, et al. New real-time interactive cardiac magnetic resonance imaging system complements echocardiography. *J Am Coll Cardiol.* 1998;32:2049-2056.
3. Kaji S, Yang PC, Kerr AB, et al. Complete Evaluation of Left Ventricular Volume and Mass in Less Than 5 Minutes With Real-Time Interactive Cardiac Magnetic Resonance Imaging System. *J Am Coll Cardiol.* 2000;35:464Abstr.

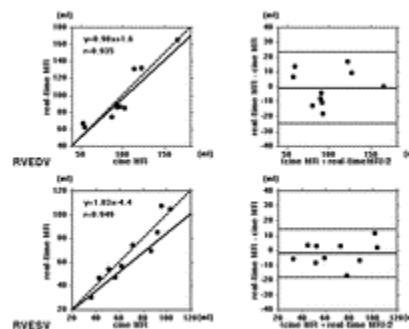


Figure 1