

Dynamic MRI and Principal Component Analysis of Finger Joints in Rheumatoid Arthritis, Polyarthritis, and Healthy Controls

M. Klarlund, M. Østergaard, E. Rostrup, H. Skjødt, I. Lorenzen

The Danish Research Center of Magnetic Resonance and Department of Rheumatology, H:S Hvidovre Hospital, Denmark

Purpose

To explore methodological aspects of dynamic magnetic resonance imaging (MRI) as an indicator of inflammatory activity in the metacarpophalangeal (MCP) joints of patients with rheumatoid arthritis (RA), early-unclassified polyarthritis, and healthy controls.

Inflamed synovium was identified using manual outlining of enhancing areas, and the rate of enhancement was calculated. Furthermore, for the first time, a principal component analysis (PCA) is presented as a new semi-automated method of identifying enhancing synovial tissue.

Introduction

Dynamic MRI of the synovium in the joint may reflect inflammatory activity and, as such, may be a possible indicator of the disease process in the joint as has been shown for knee affections (1-3). An obstacle in the evaluation of the MR images is that it is time-consuming. A less time consuming method might be the PCA.

Methods

We examined 42 RA and 23 early-unclassified polyarthritis patients, and 12 healthy controls. Dynamic MRI through the 2nd to the 5th MCP joint was obtained on a 1.0 T Siemens Impact Unit equipped with a receive-only wrap-around coil. The repeated FLASH-MR images had an imaging time of 10s each: TR 40ms;TE 12ms;flip angle 70°;slice thickness 3mm. After the fourth image, Gadolinium-DTPA (Schering), 0.1 mmol per kg of body weight, was injected intravenously. The early synovial enhancement (EE) rate was calculated ('manual method'):

$$EE\ rate = \frac{(SI(60) - SI_0)}{SI_0 \times 60} \times 100\%,$$

where SI_0 is the mean of the first 5 measurements and $SI(60)$ is the signal intensity measured 60 s after the beginning of the enhancement.

Principal component analysis (PCA) was performed for automated recognition of synovial enhancement (dichotomous variable). The PCA analysis isolates and locates the most significant sources of variation in the data material (4). The first component generally showed a temporal course compatible with inflammatory enhancement, whereas the spatial and temporal patterns of the second component were identified as vessels. Thus, the presence of voxel values exceeding the threshold of the first component but not that of the second within a joint was considered to be a sign of inflammation.

Results

The patients had higher EE rates in the 2nd to 5th MCP joints than had the healthy controls ($P<0.01$). No significant difference was found in EE rates of the two patient groups ($P>0.09$). An upper limit (mean + 2SD) of

enhancement was established for the 2nd to 5th MCP joints in the healthy control group, which served to identify abnormal EE rates in the corresponding joints of patients. Both the manual method and the PCA method identified more involved joints than did the clinical evaluation. The PCA method agreed to a greater extent with the clinical evaluation ($P<0.01$, adjusted for interdependent observations within each person) than did the manual method ($P>0.1$).

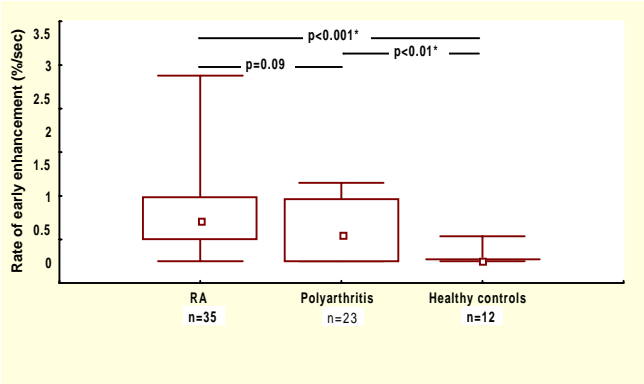


Figure 1. Box-and-whiskers plot with medians (small boxes), interquartile ranges (large boxes) and minimum and maximum values (whiskers) of the rate of early enhancement in the 2nd MCP joints of patients with RA and early-unclassified polyarthritis, and in healthy controls. P values for differences between groups are given (Mann-Whitney).

Discussion

Dynamic MRI allows quantitative estimation of the synovial enhancement in the MCP joints of patients and a healthy control group. Dynamic MRI may reflect other aspects of disease activity than those registered by clinical observations, as a number of joints with no apparent clinical affection showed enhancement. Dynamic MRI expressed as the EE rate of finger joints may be useful in the assessment of the inflammatory activity in the joints of patients with RA and unclassified polyarthritis. The PCA seems to be a promising method for automated identification of enhancing synovial tissue.

References

1. Konig H, Sieper J, Wolf KJ. *Radiology* **176**,473-477, 1990.
2. Reiser MF, Naegele M. *Magn. Reson. Imaging.* **3**,307-310, 1993.
3. Østergaard M, Stoltenberg M, Løvgreen-Nielsen M, Volck B, Sonne-Holm S, Lorenzen I. *Magn. Reson. Imaging.* **16**, 743-754, 1998.
4. Press WH, Teukolsky SA, Vetterling WT, Flannery BP. *Numerical recipes in C.* 2nd ed. Cambridge Univ. Press, 1992.

Acknowledgments

This research was supported in part by grants from the Danish Rheumatism Association and H:S forskningspulje.